

Pigmentation due to Stasis Dermatitis Treated Successfully with a Noncoherent Intense Pulsed Light Source

C.L. PIMENTEL, MD, AND M.J. RODRIGUEZ-SALIDO, MD*

The authors have indicated no significant interest with commercial supporters.

Chronic venous insufficiency is accompanied by various skin lesions. Ocre dermatitis is a secondary pigmentary disorder of venous stasis where the increase in intravascular pressure and endothelial alterations cause extravasation of erythrocytes, hemosiderine-laden macrophages, and melanin deposits. Aesthetic treatment is difficult and in most cases unsatisfactory.¹

Intense pulsed light (IPL) systems are high-intensity light sources, which emit polychromatic light. Unlike laser systems, these flashlamps work with noncoherent light in a broad-wavelength spectrum of 515 to 1,200 nm. These properties allow for great variability in selecting individual treatment parameters and adapting to different types of skin types and indications.²

Case Report

A 69-year-old Caucasian female consulted our department for treatment of pigmentary ocre dermatitis secondary to a chronic venous insufficiency of 25 years' duration. She presented purpuric macules and patches, ocre-brownish in color, on the lower third of both legs with no discomfort except her aesthetic problem (Figure 1). The patient made no reference to taking any medication or to having a medical history of interest with the exception of venous insufficiency. She had consulted various specialists who offered no solution to the aesthetic problem and who had prescribed, as a treatment, a chelating decoloring gel, which she used for several months with no

improvement. After informed consent was obtained, we chose noncoherent IPL source (Harmony system, Alma Lasers Ltd., Caesarea, Israel) as a treatment.

We performed the test spot with good results; therefore, we decided to apply the full treatment to both legs 1 month later. Three sessions were applied with the following parameters: 570 nm, 15 ms, 10 to 12 J/cm², after which lesions initially darkened and then lightened, becoming skin colored completely, after a few weeks (Figure 2). **We have not observed repigmentation after a 6-month-follow-up. No side effects occurred.**

Discussion

Just a few decades ago, before lasers were introduced into dermatologic practice, many cutaneous lesions were untreatable. Since the introduction of lasers in dermatology in the 1960s and the contribution by Anderson and Parrish in the 1980s based on the selective photothermolysis theory, lasers, and similar sources have become a main component of many dermatology practices.³

Lasers and IPL sources are frequently used for the treatment of pigmented lesions, and the appropriate selection of devices for different lesions is vital to achieving satisfactory clinical outcomes. In dark-skinned patients, the risk of postinflammatory hyperpigmentation is of particular importance. In general, long-pulse laser and IPL sources can be effective with a low risk of postinflammatory hyperpigmentation

**Both authors are affiliated with Cosmetic Dermatology and Cutaneous Laser Unit, Hospiten Rambla, Santa Cruz de Tenerife, Canary Islands, Spain*

© 2008 by the American Society for Dermatologic Surgery, Inc. • Published by Wiley Periodicals, Inc. • ISSN: 1076-0512 • *Dermatol Surg* 2008;34:950–951 • DOI: 10.1111/j.1524-4725.2008.34184.x

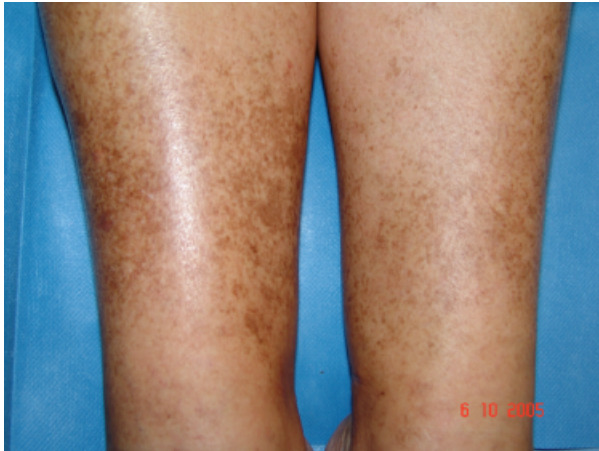

Figure 1. Purpuric macules and patches, ochre-brownish in color, on the lower third of both legs with no discomfort except her aesthetic problem.

when used for the treatment of pigmentary lesions.⁴ A pigmentary ochre dermatitis secondary to a chronic venous insufficiency causes important cosmetic disturbances, and no therapeutic options have been proposed that can guarantee good cosmetic results.

The first sign of chronic venous insufficiency is usually edema in the lower third of the legs, more pronounced in the afternoon/evening and resolved during the night. The petechiae caused by stasis and venous insufficiency lead to hemosiderin deposits corresponding to the degradation of the erythrocytary hemoglobin, which show as confluent petechial spots, dusky-brownish or ochre in color.⁵

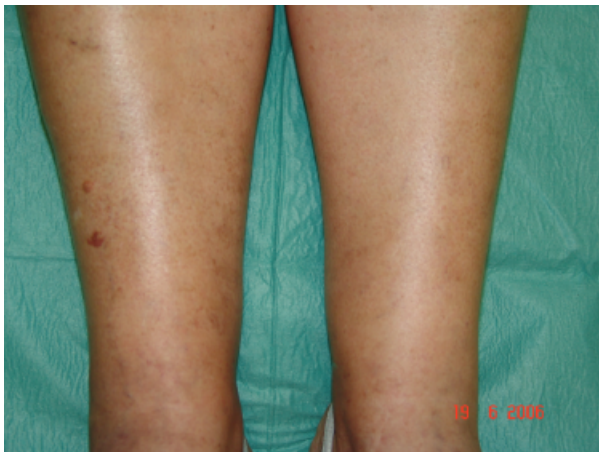


Figure 2. A few weeks after treatment.

The treatment of secondary cutaneous pigmentation of stasis dermatitis is complicated from the medical point of view, with mostly unsatisfactory results, and so, in most cases, not enough medical attention is paid. In spite of the fact that the clinical symptoms are not serious, the aesthetic factor causes considerable concern for patients, most of whom are women desiring to expose their legs.

Until now, there has been no optimum treatment for pigmentary ochre dermatitis. The use of noncoherent IPL source can be effective with a lower risk of postinflammatory hyperpigmentation, especially when used on dark-skinned patients.

In conclusion, given the excellent results obtained in our case, we suggest the use of noncoherent IPL source as a treatment to be considered in cases of pigmentation due to stasis dermatitis and other purpuric dermatosis associated with chronic vasculitis, including hypergammaglobulinemia, Sjögren's syndrome, cryoglobulins, and hepatitis C.

References

1. Fritsch P, Reidor N. Other eczematous eruptions. In: Bologna JL, Jorizzo JL, Rapini RP, eds. *Dermatology*. Elsevier Science; 2004. p. 215–26.
2. Raulin C, Greve B, Grema H. IPL technology: a review. *Lasers Surg Med* 2003;32:78–87.
3. Jones E, Nouri K. Laser treatment for pigmented lesions: a review. *J Cosmetic Dermatol* 2006;5:9–13.
4. Chan HH, Kono T. The use of lasers and intense pulsed light sources for the treatment of pigmentary lesions. *Skin Therap Lett* 2004;9:5–7.
5. Samad A, Dodds S. Acroangiodermatitis: review of the literature and report of a case associated with symmetrical foot ulcers. *Eur J Vasc Endovasc Surg* 2002;24:558–60.

Address correspondence and reprint requests to: Carmen Lucía Pimentel Villasmil, MD, Cosmetic Dermatology and Cutaneous Laser Unit, Hospiten Rambla, Rambla General Franco, 115, Sta Cruz de Tenerife 38001, Canary Island, Spain, or e-mail: lpimentel@hospiten.es